JETIR.ORG ISSN: 2349-5162 | ESTD Year : 2014 | Monthly Issue
JOURNAL OF EMERGING TECHNOLOGIES AND INNOVATIVE RESEARCH (JETIR)
An International Scholarly Open Access, Peer-reviewed, Refereed Journal

# Etiology of microcytic hypochromic anemia - A case study

**Dr. Rinkal N. Nakawala (MD)**
Associate professor in Roganidana (pathology) department, Shree O.H.Nazar Ayurveda college, surat (Gujarat)

**Abstract**

Microcytic hypochromic anemia is a distinct morphologic sub-type of anemia with well-defined etiology and treatment. The objective of this study was to determine the etiology and frequency of microcytic hypochromic anemia. This cross-sectioned observational study was conducted at Bharti medical college, Teaching hospital, BVU, COA, Pune. One hundred cases of microcytic hypochromic anemia were included. Relevant clinical history, hemogram, reticulocyte count, iron profiles were documented in a proforma. Bone marrow aspiration and hemoglobin electrophoresis was conducted when required. Diagnosis of microcytic hypochromic anemia requires a standardized approach which includes clinical details, hemogram, peripheral blood smear, reticulocyte count, iron profile, hemoglobin electrophoresis and bone marrow examination.

**Key words**: Microcytic Hypochromic; Iron; thalassaemia; Electrophoresis

## Introduction

Anemia is the most common disorder of blood. It is defined as a reduction below normal limits of the total circulating red cell mass or a reduction in the hemoglobin (Hb) concentration of the blood in comparison with the normal values for that age and sex. The morphologic approach which groups anemia by red blood cells size into microcytic if the cells are smaller than normal, normocytic if they are normal size and macrocytic if they are larger than normal.
Microcytic hypochromic anemia can be classified into Iron deficiency anemia (IDA), Anemia of chronic disorders (ACD), disorder of globin synthesis Thalassemia, disorder of porphyrin and heme synthesis Sideroblastic Anemia (SA).

Iron replacement therapy is started in many centers without investigating patients to determine the cause. It is important to follow an orderly approach in microcytic hypochromic anemia so as to correctly diagnose etiology. Prompt relief and significant improvement in patient condition can be made if the underlying etiology is recognized. On the contrary inappropriate therapy may be deleterious to the patient. Anemia due to chronic disease requires addressing the underlying cause and is not benefited by iron supplements. Iron overload is a known complication in undiagnosed thalassemia patients who are erroneously given iron therapy. Similarly reversible sideroblastic anemia due to acquired causes is treatable and requires removal of the inducing agent. Also, genetic assessment and different management is needed in suspected hereditary sideroblastic anemia. This study was intended to find the etiology of microcytic hypochromic anemia.

MATERIAL AND METHODS

There was a cross-sectional observational hospital based study conducted at Bharati hosital, BVCOA, Pune from February 2016 to December 2016. Permission was obtained from institutional review committee. One hundred microcytic hypochromic anemias on peripheral blood film (PBF) were included. Clinical history, hemogram, reticulocyte count, iron profile was documented in a proforma. Bone marrow aspiration and hemoglobin electrophoresis was conducted when required. 5 ml venous blood sample was collected in EDTA vacutainer. Another 5 ml blood was collected in a plain tube for iron profile. Wright's stain was done to examine peripheral blood films. Complete hemogram was performed in an automated haematology analyzer. Colorimetry method with colorimeter was used to measure serum iron, Total Iron Binding Capacity (TIBC), Transferrin percentage saturation. Frequency,
Percentage, mean and standard deviation of all the parameters were calculated.

Table 1: Etiology and its frequency in Iron deficiency anemia

| Causes of IDA | Number of cases (%) |
|---|---|
| DUB | 10 (20.4) |
| Pregnancy | 10 (20.4) |
| Perimenopausal bleeding | 8 (16.3) |
| Chronic kidney disease | 6 (12.2) |
| Post major gastrointestinal surgery | 4 (8.1) |
| Leiomyoma | 3 (6.1) |
| Hook worm infestation | 3 (6.1) |
| Gastirc ulcer | 3 (6.1) |
| Endometrial polyp | 2(4) |
| Endometriosis | 1(2) |
| Total | 50 (100) |

Table 2: Frequency of causes of anemia of chronic diseases

| Causes of anemia of chronic disease | Number of cases (%) |
|---|---|
| Tuberculosis | 9(21.9) |
| Diabetes Mellitus | 7(17.0) |
| Ulcerative colitis | 5(12.1) |
| Multiple Myeloma | 3(7.3) |
| Idiopathic thrombocytopenic purpura | 2(4.8) |
| Acute myeloid leukemia | 2(4.8) |
| Rectal polyp | 2(4.8) |
| Rheumatoid arthritis | 2(4.8) |
| Non- Hodgkin lymphoma | 2(4.8) |
| Perianal fistula | 2(4.8) |
| Pancreatic carcinoma with metastasis | 2(4.8) |
| Lung cancer | 2(4.8) |
| Crohn's disease | 2(4.8) |
| Chronic osteomyelitis | 2(4.8) |
| Adrenal carcinoma | 3(7.3) |
| Systemic lupus erythematosus | 3(7.3) |
| Total | 50(100) |
| | |

RESULTS

Of 100 peripheral blood smears of patients with microcytic hypochromic anemia (fig.1), 49% were due to IDA and 41 % were anemia of chronic disease. Hemolytic anemia including sickle cell anemia (fig.2) accounted for 5 % cases. Sideroblastic anemia was seen in 1 % and in 4 % the cause could not be determined. Etiology of IDA is shown in table 1. Dysfunctional uterine bleeding (DUB) was the commonest cause of iron deficiency (20.4%).

Mean value of Mean Corpuscular Volume (MCV) was lowest in IDA (70 fl). Mean value of red cell distribution width (RDW) was highest in IDA (16.4 %) while it was normal in hemolytic anemia (14 %) which is shown in Table 3.

Mean value of serum iron was reduced in IDA (32.2 ug/dl) and ACD ( 34.8 ug/dl). It was normal in hemolytic anemia (83 ug/dl) and was raised in SA (295ug/dl). Mean serum ferritin was reduced in IDA (7.6 ng/ml), raised in ACD (158.6ng/ml) and normal in hemolytic anemia (99.2 ng/ml). Serum ferritin was normal in SA (93ug/ml). The mean TIBC was raised in IDA (458 ug/ml) and normal in other causes of microcytic hypochromic anemia. Table 4. Five out of the nine patients on whom electrophoresis was done showed abnormal Hb bands. Three were cases of beta-thalassemiatrait (fig. 3), one was case Beta-thalassemia major and one patients was diagnosed as sickle cell trait. (Table 5)

Table 3 : Mean values of Hb and RBC indices

| Type | Hb (g/dl) (Mean + S.D.) | MCV (fl) (Mean + S.D.) | RDW (%) (Mean + S.D.) |
|---|---|---|---|
| ACD | 9.41 + 1.76 | 82.86 + 5.077 | 16.06 + 1.10 |
| IDA | 9.89 + 1.20 | 78.40 + 5.07 | 16.46 + 2.13 |
| Hemolytic anemia | 9.22 + 1.32 | 71.0 + 7.6 | 14.00 + 1.78 |
| Sideroblastic anemia | 9 | 82 | 18 |

Table 4 : Mean values of Iron profile

| Type | Iron (ug/dl) Mean+SD | Ferritin (ng/ml) Mean+SD | TIBC (ug/dl) Mean+SD | Transferrin (% saturation) Mean+SD) |
|---|---|---|---|---|
| ACD | 34.81 + 17.92 | 158.60 + 30.64 | 305.54 + 16.40 | 13.42 + 6.27 |
| IDA | 32.38 + 13.23 | 7.6 + 3.90 | 458.31 + 74.36 | 6.10 + 3.72 |
| Hemolytic anemia | 83.20 + 12.43 | 99.20 + 23.20 | 301.80 + 19.16 | 27.60 + 4.43 |
| Sideroblastic anemia | 295.0 | 93.00 | 163.00 | 180.00 |

Table 5: Hb electrophoresis findings

| Type of band | Diagnosis | Number of cases |
|---|---|---|
| HbA+HbF | Beta thalassemia major | 1 |
| HbA + HbA2 + HbF | Beta thalassemia trait | 3 |
| HbS + HbA | Sickle cell trait | 1 |

DISCUSSION

Microcytic hypochromic anemia is a distinct morphological subgroup characterized by significant reduction in red cell size combined with increased central pallor of the red cells. The etiology is well defined and an orderly approach has been established in arriving at a definite diagnosis. Similar to this study, in most series iron deficiency anemia and thalassemia trait were the commonest causes of a microcytic hypochromic blood picture.DUB resulting in blood loss was the commonest cause of IDA in this study. Anemia of chronic disease is the second most prevalent cause of anemia after iron deficiency anemia. Advanced disease causes microcytic hypochromic appearance of red cells. It is commonly associated with chronic infections, inflammatory or neoplastic disorders and is characterized by hypoferremia. Anemia of chronic disease does

not include anemia caused by renal or hepatic insufficiency. Recent observations have however shown that apart from infections, inflammation and malignancy, ACD can be seen in a variety of conditions including severe trauma, diabetes mellitus and anemia of the elderly. Anemia of chronic disease remains under recognized and under treated.

The diagnosis of pure IDA or ACD is straight forward in some situations however, conventional laboratory tests for iron status are influenced by the inflammatory response and their diagnostic accuracy may be undermined. Hemolytic anemia was suspected in 5 cases on peripheral smear. Morphology of thalassemia trait and iron deficiency anemia is similar on peripheral smear. Hb electrophoresis is mandatory in distinguishing the two. The principal limitation of Hb electrophoresis that it may miss thalassemia trait with low percentage of HbF and HbA2. This can be overcome by use of High performance liquid chromatography (HPLC) which quantifies levels of Hb even below 5%.

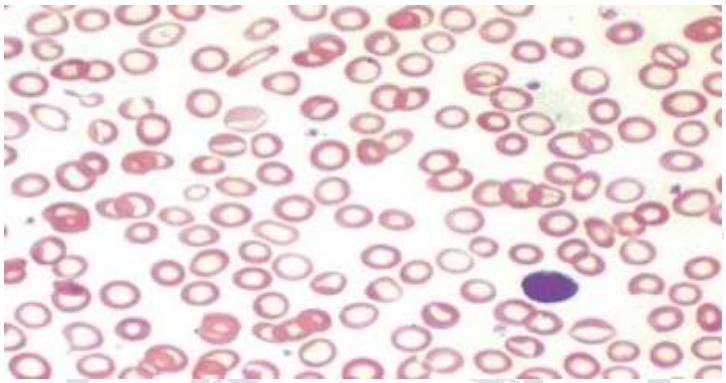

Photomicrograph showing microcytic hypochromic anemia with marked anisopoikilocytosis (Wright's stain X100)




Figure 2 : Photomicrograph showing positive sickling test (Unstained film X100)

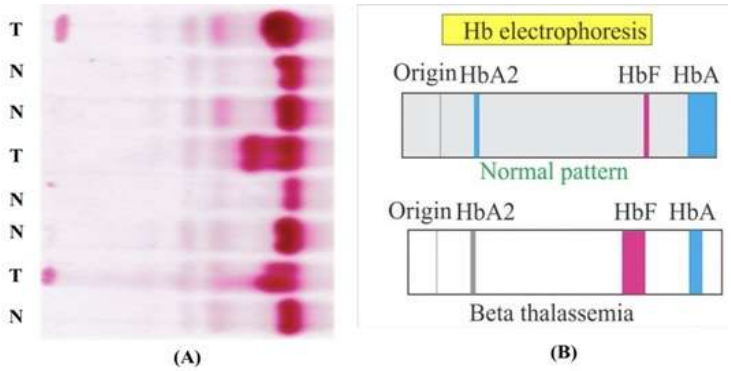


Figure 3 : Photomicrograph of beta thalassemia trait in Hb electrophoresis cellulose

CONCLUSION

Microcytic hypochromic anemia has a diverse etiology. Microcytic hypochromic anemia is detected with the help of hemogram and peripheral blood film. Serum iron profile, bone marrow iron stain and Hb electrophoresis are a must for confirmation of etiology.

The primary conclusion regarding the etiology of microcytic hypochromic anemia is that the most frequent cause is iron deficiency, which can result from insufficient dietary intake, poor absorption or chronic blood loss. However, other significant causes include thalassemias, anemia of chronic disease and SA. Therefore, a definitive diagnosis requires distinguishing between these varied causes, which can include iron studies, genetic testing and other evaluation depending upon the patient's clinical presentation.

**REFERENCES**

1. Weiss G. Pathogenesis and treatment of anemia of chronic disease Blood.Rev 2002;16:87-96 Crossref
2. Cell J, Sami K, Perrier A, Reny JI. Iron deficiency anemia, anemia of chronic disease and mixed anemia. How ro determine the diagnosis ? Rev Med Suisse 2011;7 2018-3 Crosscef
3. Price EA, Schrier St. Unexplained aspect of anemia of inflammation Adv Hematol 2010;2010
4. Aster JC. Red Blood cell and bleeding disorders. In Kumar V, Abbs AK, Favsto N. Robbins abd Cortan pathology. Basics of disease: 7th edition Noida, India Elsevier p 622-3
5. Hallberg L, el. Menstrual blood loss and iron deficiency Acta Med Scand J Clin Lab Invest 1964, 16:244. crossref
6. Upichard W. investigating Microcytic anemia BMJ 2013; 346
7. Hoffman R. Benz EJ Jr. Shattil SJ. Hematology basic principles and practices approach to anemia in the adult and child. Churchill Livingstone;1998 p 439-446